

World Journal of *Clinical Cases*

World J Clin Cases 2018 December 6; 6(15): 869-1072



REVIEW

- 869 Biomarkers in colorectal cancer: Current clinical utility and future perspectives
Vacante M, Borzi AM, Basile F, Biondi A
- 882 Inflammation and de-differentiation in pancreatic carcinogenesis
Seimiya T, Otsuka M, Iwata T, Tanaka E, Suzuki T, Sekiba K, Yamagami M, Ishibashi R, Koike K

MINIREVIEWS

- 892 Management of gastroesophageal reflux disease: Patient and physician communication challenges and shared decision making
Klenzak S, Danelisen I, Brannan GD, Holland MA, van Tilburg MA
- 901 Non-small bowel lesion detection at small bowel capsule endoscopy: A comprehensive literature review
Koffas A, Laskaratos FM, Epstein O

ORIGINAL ARTICLE

Case Control Study

- 908 Genetic associations of inflammatory bowel disease in a South Asian population
Niriella MA, Liyanage IK, Kodisinghe SK, De Silva AP, Rajapakshe N, Nanayakkara SD, Luke D, Silva T, Nawarathne M, Peiris RK, Kalubovila UP, Kumarasena SR, Dissanayake VH, Jayasekara RW, de Silva HJ
- 916 Clinical relevance of atrial septal aneurysm and patent foramen ovale with migraine
He L, Cheng GS, Du YJ, Zhang YS

Retrospective Study

- 922 Current trends of liver cirrhosis in Mexico: Similitudes and differences with other world regions
Méndez-Sánchez N, Zamarripa-Dorsey F, Panduro A, Purón-González E, Coronado-Alejandro EU, Cortez-Hernández CA, Higuera de la Tijera F, Pérez-Hernández JL, Cerda-Reyes E, Rodríguez-Hernández H, Cruz-Ramón VC, Ramírez-Pérez OL, Aguilar-Olivos NE, Rodríguez-Martínez OF, Cabrera-Palma S, Cabrera-Álvarez G
- 931 Retrograde intrarenal surgery vs miniaturized percutaneous nephrolithotomy to treat lower pole renal stones 1.5-2.5 cm in diameter
Li MM, Yang HM, Liu XM, Qi HG, Weng GB

Clinical Trials Study

- 936 Comparative study on operative trauma between microwave ablation and surgical treatment for papillary thyroid microcarcinoma
Xu B, Zhou NM, Cao WT, Gu SY

Observational Study

- 944 Association between functional abdominal pain disorders and asthma in adolescents: A cross-sectional study
Kumari MV, Devanarayana NM, Amarasiri L, Rajindrajith S

Prospective Study

- 952 Evaluating mucosal healing using colon capsule endoscopy predicts outcome in patients with ulcerative colitis in clinical remission
Takano R, Osawa S, Uotani T, Tani S, Ishida N, Tamura S, Yamade M, Iwaizumi M, Hamaya Y, Furuta T, Miyajima H, Sugimoto K

META-ANALYSIS

- 961 Probiotic Medilac-S[®] for the induction of clinical remission in a Chinese population with ulcerative colitis: A systematic review and meta-analysis
Sohail G, Xu X, Christman MC, Tompkins TA
- 985 Impact of body mass index on short-term outcomes of laparoscopic gastrectomy in Asian patients: A meta-analysis
Chen HK, Zhu GW, Huang YJ, Zheng W, Yang SG, Ye JX
- 995 Scoring systems for prediction of mortality in decompensated liver cirrhosis: A meta-analysis of test accuracy
Wu SL, Zheng YX, Tian ZW, Chen MS, Tan HZ

CASE REPORT

- 1007 Gangrenous cholecystitis: A silent but potential fatal disease in patients with diabetic neuropathy. A case report
Mehrzad M, Jehle CC, Roussel LO, Mehrzad R
- 1012 Successful endovascular treatment of endoscopically unmanageable hemorrhage from a duodenal ulcer fed by a renal artery: A case report
Anami S, Minamiguchi H, Shibata N, Koyama T, Sato H, Ikoma A, Nakai M, Yamagami T, Sonomura T

- 1018** Didactic surgical experience of thyroid metastasis from renal cell carcinoma: A case report
Yamauchi M, Kai K, Shibamiya N, Shimazu R, Monji M, Suzuki K, Kakinoki H, Tobu S, Kuratomi Y
- 1024** Gastric cancer with severe immune thrombocytopenia: A case report
Zhao ZW, Kang WM, Ma ZQ, Ye X, Yu JC
- 1029** Injury to the axillary artery and brachial plexus caused by a closed floating shoulder injury: A case report
Chen YC, Lian Z, Lin YN, Wang XJ, Yao GF
- 1036** Pancreatic panniculitis and solid pseudopapillary tumor of the pancreas: A case report
Zhang MY, Tian BL
- 1042** Intermittent abdominal pain accompanied by defecation difficulties caused by Chilaiditi syndrome: A case report
Luo XG, Wang J, Wang WL, Yu CZ
- 1047** Endoscopic titanium clip closure of gastric fistula after splenectomy: A case report
Yu J, Zhou CJ, Wang P, Wei SJ, He JS, Tang J
- 1053** Successful steroid treatment for acute fibrinous and organizing pneumonia: A case report
Ning YJ, Ding PS, Ke ZY, Zhang YB, Liu RY
- 1059** Sub-Tenon's urokinase injection-assisted vitrectomy in early treatment of suprachoroidal hemorrhage: Four cases report
Chai F, Ai H, Deng J, Zhao XQ
- 1067** Plexiform fibromyxoma of the small bowel: A case report
Zhang WG, Xu LB, Xiang YN, Duan CH

ABOUT COVER

Editorial Board Member of *World Journal of Clinical Cases*, Steven M Schwarz, MD, Professor, Department of Pediatrics, Children's Hospital at Downstate, SUNY-Downstate Medical Center, Brooklyn, NY 11203, United States

AIM AND SCOPE

World Journal of Clinical Cases (*World J Clin Cases*, *WJCC*, online ISSN 2307-8960, DOI: 10.12998) is a peer-reviewed open access academic journal that aims to guide clinical practice and improve diagnostic and therapeutic skills of clinicians.

The primary task of *WJCC* is to rapidly publish high-quality Autobiography, Case Report, Clinical Case Conference (Clinicopathological Conference), Clinical Management, Diagnostic Advances, Editorial, Field of Vision, Frontier, Medical Ethics, Original Articles, Clinical Practice, Meta-Analysis, Minireviews, Review, Therapeutics Advances, and Topic Highlight, in the fields of allergy, anesthesiology, cardiac medicine, clinical genetics, clinical neurology, critical care, dentistry, dermatology, emergency medicine, endocrinology, family medicine, gastroenterology and hepatology, geriatrics and gerontology, hematology, immunology, infectious diseases, internal medicine, obstetrics and gynecology, oncology, ophthalmology, orthopedics, otolaryngology, pathology, pediatrics, peripheral vascular disease, psychiatry, radiology, rehabilitation, respiratory medicine, rheumatology, surgery, toxicology, transplantation, and urology and nephrology.

INDEXING/ABSTRACTING

World Journal of Clinical Cases (*WJCC*) is now indexed in PubMed, PubMed Central, Science Citation Index Expanded (also known as SciSearch®), and Journal Citation Reports/Science Edition. The 2018 Edition of Journal Citation Reports cites the 2017 impact factor for *WJCC* as 1.931 (5-year impact factor: N/A), ranking *WJCC* as 60 among 154 journals in Medicine, General and Internal (quartile in category Q2).

EDITORS FOR THIS ISSUE

Responsible Assistant Editor: *Xiang Li*
Responsible Electronic Editor: *Wen-Wen Tan*
Proofing Editor-in-Chief: *Lian-Sheng Ma*

Responsible Science Editor: *Ying Dou*
Proofing Editorial Office Director: *Jin-Lei Wang*

NAME OF JOURNAL
World Journal of Clinical Cases

ISSN
 ISSN 2307-8960 (online)

LAUNCH DATE
 April 16, 2013

FREQUENCY
 Semimonthly

EDITORS-IN-CHIEF
Sandro Vento, MD, Department of Internal Medicine, University of Botswana, Private Bag 00713, Gaborone, Botswana

EDITORIAL BOARD MEMBERS
 All editorial board members resources online at <http://www.wjgnet.com/2307-8960/editorialboard.htm>

EDITORIAL OFFICE
 Jin-Lei Wang, Director

World Journal of Clinical Cases
 Baishideng Publishing Group Inc
 7901 Stoneridge Drive, Suite 501, Pleasanton, CA 94588, USA
 Telephone: +1-925-2238242
 Fax: +1-925-2238243
 E-mail: editorialoffice@wjgnet.com
 Help Desk: <http://www.f6publishing.com/helpdesk>
<http://www.wjgnet.com>

PUBLISHER
 Baishideng Publishing Group Inc
 7901 Stoneridge Drive, Suite 501, Pleasanton, CA 94588, USA
 Telephone: +1-925-2238242
 Fax: +1-925-2238243
 E-mail: bpgoffice@wjgnet.com
 Help Desk: <http://www.f6publishing.com/helpdesk>
<http://www.wjgnet.com>

PUBLICATION DATE
 December 6, 2018

COPYRIGHT
 © 2018 Baishideng Publishing Group Inc. Articles published by this Open Access journal are distributed under the terms of the Creative Commons Attribution Non-commercial License, which permits use, distribution, and reproduction in any medium, provided the original work is properly cited, the use is non commercial and is otherwise in compliance with the license.

SPECIAL STATEMENT
 All articles published in journals owned by the Baishideng Publishing Group (BPG) represent the views and opinions of their authors, and not the views, opinions or policies of the BPG, except where otherwise explicitly indicated.

INSTRUCTIONS TO AUTHORS
<http://www.wjgnet.com/bpg/gerinfo/204>

ONLINE SUBMISSION
<http://www.f6publishing.com>

Clinical Trials Study

Comparative study on operative trauma between microwave ablation and surgical treatment for papillary thyroid microcarcinoma

Bin Xu, Ning-Ming Zhou, Wei-Tian Cao, Shu-Yan Gu

Bin Xu, Ning-Ming Zhou, Wei-Tian Cao, Shu-Yan Gu, Department of Ultrasound, Fudan University Affiliated Shanghai Fifth People's Hospital, Shanghai 200240, China

ORCID number: Bin Xu (0000-0002-9184-107X); Ning-Ming Zhou (0000-0001-8424-7825); Wei-Tian Cao (0000-0002-4880-7589); Shu-Yan Gu (0000-0003-4596-6354).

Author contributions: Xu B and Zhou NM designed the research; Xu B and Cao WT performed the research; Gu SY contributed new analytic tools; Xu B analyzed the data; and Xu B, Zhou NM, and Cao WT wrote the paper.

Support by Minhang District Natural Science Research Project, No. 2013MHZ003.

Institutional review board statement: The study was approved by the Ethics Committee of Fudan University Affiliated Shanghai Fifth People's Hospital.

Clinical trial registration statement: This study is registered at Chinese Clinical Trial Registry. The registration number is ChiCTR1800018512.

Informed consent statement: All patients gave informed consent to this study.

Conflict-of-interest statement: The authors declare that they have no competing interests.

Data sharing statement: No additional data are available.

Open-Access: This article is an open-access article which selected by an in-house editor and fully peer-reviewed by external reviewers. It distributed in accordance with the Creative Commons Attribution Non Commercial (CC BY-NC 4.0) license, which permits others to distribute, remix, adapt, build upon this work non-commercially, and license their derivative works on different terms, provided the original work is properly cited and the use is non-commercial. See: <http://creativecommons.org/licenses/by-nc/4.0/>

Manuscript source: Unsolicited manuscript

Corresponding author to: Ning-Ming Zhou, MD, Chief Doctor, Department of Ultrasound, Fudan University Affiliated Shanghai Fifth People's Hospital, 128 Ruili Road, Minhang District, Shanghai 200240, China. zhouningming@5thhospital.com
Telephone: +86-21-24289356

Received: September 27, 2018

Peer-review started: September 27, 2018

First decision: October 18, 2018

Revised: October 25, 2018

Accepted: November 7, 2018

Article in press: November 7, 2018

Published online: December 6, 2018

Abstract

AIM

To compare the effect and postoperative trauma of ultrasound-guided percutaneous microwave ablation and surgical resection in the treatment of papillary thyroid microcarcinoma (PTMC).

METHODS

Eighty-seven patients with PTMC treated at Fudan University affiliated Shanghai Fifth People's Hospital were enrolled as subjects. The patients were divided into a microwave ablation group (41 cases) and a surgical group (46 cases). The operative time, intraoperative blood loss, length of hospital stay, serum C-reactive protein (CRP), interleukin-6 (IL-6), tumor necrosis factor- α (TNF- α), thyroid-related hormonal changes, and complications 7 d and 30 d after surgery were observed.

RESULTS

The operative time, intraoperative blood loss, and len-

gth of hospital stay in the surgical group were significantly higher than those in the microwave ablation group ($P < 0.05$). The levels of CRP, IL-6, and TNF- α in the surgical group were significantly higher than those in the microwave ablation group ($P < 0.05$). The free triiodothyronine (FT3) and free thyroxin (FT4) levels in the surgical group were significantly lower than those in the microwave ablation group ($P < 0.05$). However, the postoperative thyroid stimulating hormone (TSH) level was significantly higher than that in the microwave ablation group ($P < 0.05$). There were significant interactions between the FT3, FT4, and TSH 7 d and 30 d after operation and the treatment methods ($P < 0.05$). There was no significant difference in the complications between the two groups ($P > 0.05$).

CONCLUSION

Microwave ablation for papillary microcarcinoma of the thyroid gland has less trauma to the body, quicker recovery, and no scars. It can effectively shorten the length of hospital stay and improve the quality of life of patients.

Key words: Thyroidectomy; Body trauma; Ultrasound; Microwave ablation; Papillary thyroid microcarcinoma

© **The Author(s) 2018.** Published by Baishideng Publishing Group Inc. All rights reserved.

Core tip: Although thyroidectomy is the standard treatment for papillary thyroid microcarcinoma (PTMC), it causes great trauma to the patient's body. In recent years, there have been reports on microwave ablation for patients with PTMC, but the efficacy is not certain. This study aimed to compare the efficacy and the impact on body trauma using ultrasound-guided percutaneous microwave ablation for PTMC and surgical resection. The results showed that microwave ablation for PTMC has less trauma, quicker recovery, and no scars, which can effectively shorten the hospitalization time and improve the quality of life.

Xu B, Zhou NM, Cao WT, Gu SY. Comparative study on operative trauma between microwave ablation and surgical treatment for papillary thyroid microcarcinoma. *World J Clin Cases* 2018; 6(15): 936-943 Available from: URL: <http://www.wjgnet.com/2307-8960/full/v6/i15/936.htm> DOI: <http://dx.doi.org/10.12998/wjcc.v6.i15.936>

INTRODUCTION

With the popularization of thyroid ultrasonography and the wide application of ultrasound-guided fine needle aspiration, the detection rate of papillary thyroid microcarcinoma (PTMC) is increasing over time^[1,2]. At present, thyroidectomy is still the standard treatment method. However, the patient's physical and psychological trauma caused by surgery is extremely high. Hemorrhage

during the operation may easily damage the adjacent vital structures such as the parathyroid gland and the recurrent laryngeal nerve, causing complications such as hoarseness after surgery and leading to greater damage to the patient^[3-5]. With the rapid development of minimal invasive techniques, **ultrasound-guided microwave ablation has the advantages of small injury, short treatment time, effective curative effect, little effect on the surrounding structure and patient appearance, rapid recovery after ablation, no need for lifelong medication, etc.** However, it is mainly used for treatment of thyroid benign nodules^[6-8]. In recent years, microwave ablation has also been reported for some patients with PTMC and achieved good results^[9-11]. However, the current clinical value of ultrasound-guided microwave ablation for PTMC has not yet reached a consensus and it cannot accurately judge whether this new treatment can replace traditional surgery. Therefore, the present study aimed to compare the impact of ultrasound-guided percutaneous microwave ablation of PTMC vs surgical resection on body trauma.

MATERIALS AND METHODS

General information

Totally 87 patients with PTMC diagnosed by ultrasound guided fine-needle aspiration biopsy (FNAB) at Fudan University Affiliated Shanghai Fifth People's Hospital from January 2012 to October 2017 were included. The maximum diameter of nodules was less than 1.0 cm. Microwave ablation or surgery was selected based on the patient's own condition and their wishes. The microwave ablation group consisted of 41 patients including 12 males and 29 females and aged from 24 to 65 years with an average age of 45.11 ± 7.28 years (Table 1). The inclusion criteria were: (1) Papillary microcarcinoma of the thyroid gland confirmed by FNAB; (2) Maximum tumor diameter ≤ 1.0 cm, not close to the capsule (distance > 2.0 mm), no obvious abnormality of the contralateral thyroid gland, and no large neck lymphadenopathy or metastatic lymph nodes; and (3) Ultrasound imaging had a clear needle path. Patients with severe heart or lung diseases or poor general condition which cannot tolerate surgery or those who rejected the surgery or were anxious about the disease for treatment were excluded.

Instrument

The GE Voluson E8 ultrasound diagnostic device with a line array probe (frequency from 5 to 10 MHz) was used. Microwave ablation was performed using Nanjing Kangyou KY-2000 microwave ablation instrument and the frequency was 2450 MHz with continuous adjustable output power from 10 to 100 W. Microwave ablation instrument is connected with a 16 G cold-cycle Thy-ablation microwave antenna through a low loss coaxial cable.

Table 1 General clinical data between the two groups of patients

Group	Case	Age (yr)	Gender		Maximum diameter of nodule (mm)
			Male	Female	
Surgery group	46	46.2 ± 11.5	16	30	8.13 ± 1.22
Microwave Ablation group	41	45.8 ± 10.2	12	29	8.87 ± 1.01
<i>t/χ²-value</i>		0.171		0.302	-3.061
<i>P-value</i>		0.865		0.583	0.003

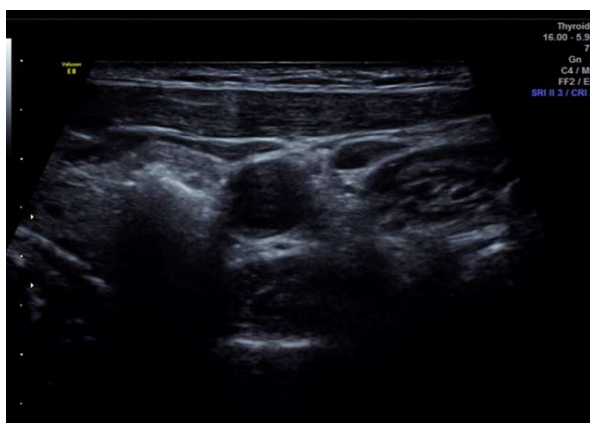

Figure 1 Ultrasound image of microwave ablation of thyroid tumors.

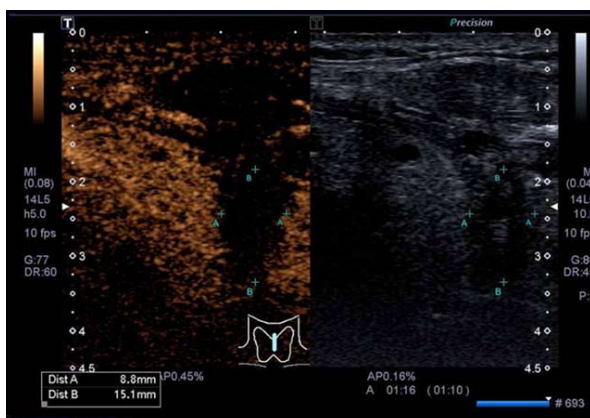


Figure 2 Two-dimensional and contrast-enhanced ultrasound images (no lesions intensified, completely ablated).

Surgical methods

Surgery group: A 5 cm long transverse incision was made 2 cm above the sternal fossa. Radical resection of the PTMC (the affected side of the thyroid and isthmus resection + lymph node dissection of the affected side VI) was adopted. Negative pressure drainage was performed after surgery.

Microwave ablation group: After the patient was intubated under general anesthesia, the patient was kept in a supine position. The saline was injected around the thyroid capsule according to the location of the tumor to form a “liquid barrier.” After ultrasound guided percutaneous puncture, the microwave antenna was

placed into the tumor (Figure 1). The ablation power was set at 50 W and the ablation time was set at 60-300 s. Extensive ablation of the tumor was performed. After the tumor was ablated, the ablation needle was slowly withdrawn to prevent the tumor cells from being transplanted along the needle path. Ultrasound angiography was used postoperatively to determine if ablation was complete (Figure 2).

Observation indicators

The operative time, intraoperative loss blood, length of hospital stay, serum C-reactive protein (CRP), interleukin-6 (IL-6), and tumor necrosis factor- α (TNF- α) 24 h after operation, thyroid hormone-related changes, and complications 7 d and 30 d after operation were observed.

Statistical analysis

SPSS19.0 software was used for data analyses. Measured data are expressed as mean \pm SD and the two groups were compared using the independent samples *t*-test. The number of cases or percentages of count data is expressed and comparison between the two groups was performed using the χ^2 test. Repeated measures analysis of variance was used to compare the levels of hormones [T3, T4, thyroid stimulating hormone (TSH)] preoperatively, 7 d after surgery, and 30 d after surgery. *P* < 0.05 was considered statistically significant.

RESULTS

Clinical indicators

The surgical time, blood loss volume, and length of hospital stay in the surgical group were significantly higher than those in the microwave ablation group (*P* < 0.05) (Table 2).

Postoperative serum markers

The levels of CRP, IL-6, and TNF- α in the surgical group were significantly higher than those in the microwave ablation group (*P* < 0.05) (Table 3).

Thyroid hormone indexes before, 7 d after, and 30 d after operation

The hormone levels of the two groups (including the hormone levels of T3, T4, and TSH) were recorded before, 7 d after, and 30 d after surgery (Tables 4-6

Table 2 Clinical indicators between the two groups (mean ± SD)

Group	Case	Length of hospital stay (d)	Blood loss volume (mL)	Surgical time (min)
Surgery group	46	4.18 ± 0.55	33.12 ± 5.07	78.81 ± 12.19
Microwave Ablation group	41	1.77 ± 0.71	10.32 ± 1.65	25.02 ± 4.14
<i>t</i> -value		17.832	27.511	26.892
<i>P</i> -value		0	0	0

Table 3 Comparison of postoperative serum markers (mean ± SD)

Group	Case	CRP (mg/L)	IL-6 (ng/L)	TNF-α (ng/L)
Surgery group	46	12.05 ± 2.57	14.44 ± 4.61	51.39 ± 2.86
Microwave Ablation group	41	0.71 ± 0.39	4.02 ± 1.78	43.55 ± 5.03
<i>t</i> -value		27.951	13.591	9.059
<i>P</i> -value		0	0	0

CRP: C-reactive protein; IL-6: Interleukin-6; TNF-α: Tumor necrosis factor-α.

Table 4 Free triiodothyronine levels between the two groups before, 7 d after, and 30 d after treatment

FT3 (pmol/L)	Preoperative	7 d after surgery	30 d after surgery
Microwave ablation group	4.28 ± 0.49	4.25 ± 0.45	4.22 ± 0.53
Surgery group	4.33 ± 0.78	3.09 ± 0.64	2.78 ± 0.84

$F_{intra-group} = 6.435$, $P_{intra-group} = 0.000$; $F_{inter-group} = 8.546$, $P_{inter-group} = 0.000$; $F_{interaction} = 45.291$, $P_{interaction} = 0.000$. FT3: Free triiodothyronine.

Table 5 Comparison of free thyroxin levels before, 7 d after, and 30 d after treatment

FT4 (pmol/L)	Preoperative	7 d after surgery	30 d after surgery
Microwave ablation group	12.33 ± 1.51	12.87 ± 2.66	12.67 ± 2.83
Surgery group	12.72 ± 1.68	10.77 ± 2.25	9.45 ± 2.07

$F_{intra-group} = 0.866$, $P_{intra-group} = 0.221$; $F_{inter-group} = 9.257$, $P_{inter-group} = 0.000$; $F_{interaction} = 31.378$, $P_{interaction} = 0.000$. FT4: Free thyroxin.

Table 6 Thyroid stimulating hormone levels between the two groups before, 7 d after, and 30 d after treatment

TSH (mIU/L)	Preoperative	7 d after surgery	30 d after surgery
Microwave ablation group	2.11 ± 1.47	1.42 ± 0.91	1.08 ± 1.35
Surgery group	2.09 ± 1.01	13.44 ± 2.37	18.43 ± 2.67

$F_{intra-group} = 55.165$, $P_{intra-group} = 0.221$; $F_{inter-group} = 67.234$, $P_{inter-group} = 0.000$; $F_{interaction} = 75.443$, $P_{interaction} = 0.000$. TSH: Thyroid stimulating hormone.

and Figure 3). According to preoperative data analysis, there was no significant difference in thyroid hormone levels between the microwave ablation group and the surgery group ($P > 0.05$). Repeated measurement analysis of variance within the group found that free triiodothyronine (FT3) levels decreased significantly postoperatively compared with preoperative values ($P < 0.05$). In contrast, TSH levels increased significantly postoperatively compared with preoperative values ($P < 0.05$). Free thyroxin (FT4) levels had no significant changes after surgery ($P > 0.05$). Comparison between groups revealed that the FT3 and FT4 levels in the surgery group were significantly lower than those in

the microwave ablation group ($P < 0.05$). The postoperative TSH level was significantly higher than that in the microwave ablation group ($P < 0.05$). There were significant interactions between the FT3, FT4, and TSH changes 7 and 30 d postoperatively and the treatment plan ($P < 0.05$).

Complications in patients

In the recovery process of the two groups, patients had different degrees of pharyngeal discomfort, hoarseness, pain, parathyroid injury, incision infection, or other complications. Those patients returned to normal after 3 mo. There were no significant difference in the compli-

Table 7 Postoperative complications in patients

Group	Microwave ablation group (n = 41)	Surgery group (n = 46)	χ^2	P
Pharyngeal discomfort	0	1	1.508	0.219
Hoarseness	1	2		
Pain	0	1		
parathyroid injury	0	0		
Incision infection	0	1		
Cough after drinking water	1	2		
Incidence of complications	4.9%	15.2%		

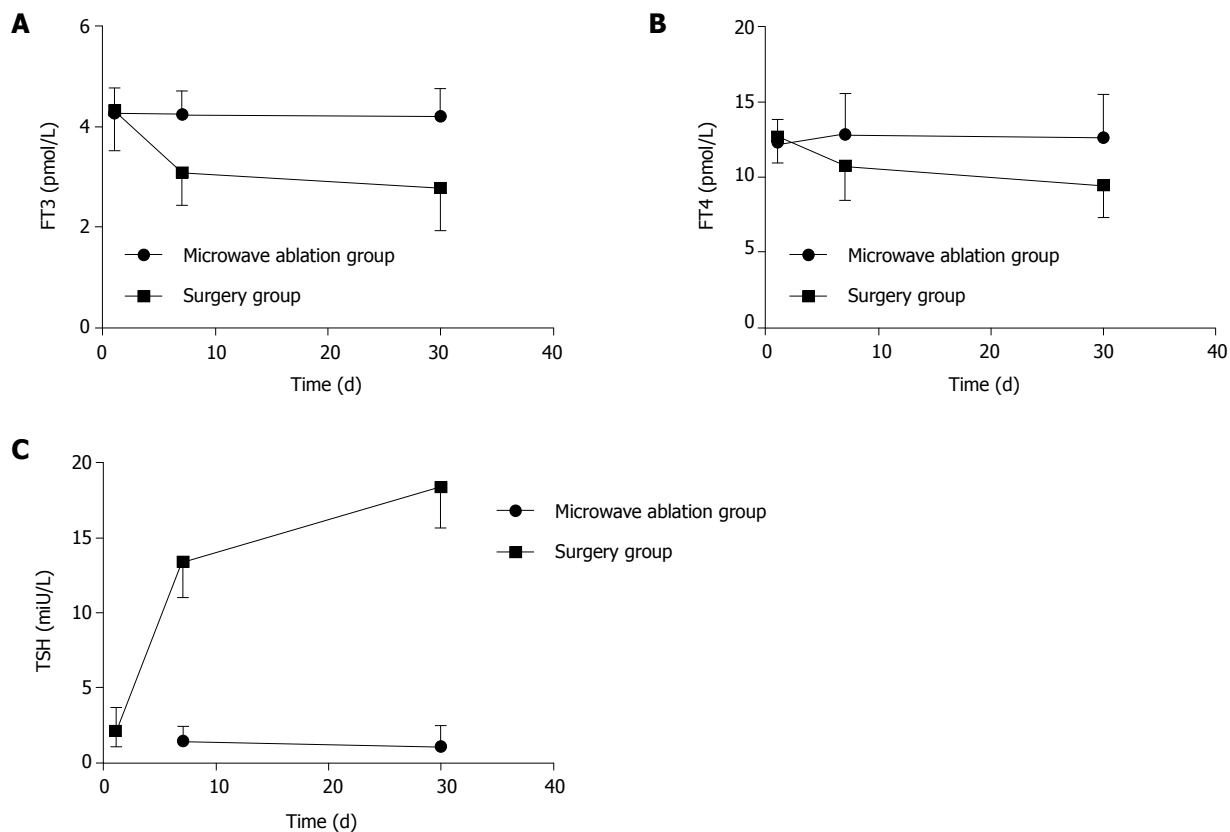


Figure 3 Trend of free triiodothyronine (A), free thyroxin (B), and thyroid stimulating hormone levels before, 7 d after, and 30 d after treatment. FT3: Free triiodothyronine; FT4: Free thyroxin; TSH: Thyroid stimulating hormone.

cations between the two groups ($P > 0.05$) (Table 7).

DISCUSSION

The direction of modern surgical development is minimally invasive treatment that is to achieve the purpose of treatment with minimal surgical trauma and to minimize the impact of surgical trauma on the body. At present, the standard treatment for single PTMC is still surgical lobectomy, which is unacceptable to some patients because of its disadvantages such as large trauma, long recovery time, and medication for life^[12-15]. Given that papillary thyroid cancer has "moderate" biological behavior, it is slow-growing and some patients carry no progression during their lifetime. Therefore, it is particularly necessary to find a therapeutic method that is effective, safe, minimally invasive, and more

aesthetically pleasing. Microwave ablation is guided by ultrasound to make the microwave ablation electrode enter into the target tissue and ablate it through rapid hyperthermia coagulation necrosis, necrotic tissue will be absorbed by the body over time and ultimately achieve the purpose of treatment with the advantages of minimal trauma, rapid recovery, easy to use, etc^[16-19]. This study compared the impact of ultrasound-guided percutaneous microwave ablation and surgical resection of PTMC on body trauma in order to explore the clinical value of ultrasound-guided microwave ablation of PTMC.

The surgical time, intraoperative blood loss, and length of hospital stay in the surgery group were significantly higher than those in the microwave ablation group ($P < 0.05$), indicating that microwave ablation of PTMC can significantly reduce the trauma to the patient. It is known that microwave ablation and surgical trauma

as external environmental stimuli can both cause the body's non-infectious stress response. The size and duration of stress response after surgery reflect the severity of surgical trauma^[20,21]. Therefore, lower trauma during surgery can reduce the body's stress response. In terms of reflecting the stress response of the body, it is known that CRP is synthesized by the liver and can be significantly elevated under stress conditions. The more severe the trauma, the more obvious the increase of CRP^[22,23]. IL-6 is a multi-functional cytokine that is mainly produced by monocytes/macrophages and T cells and is extremely low in normal human plasma. Many pathological factors can affect the production of IL-6. Surgical trauma is one of the important factors. IL-6 is now considered to be a sensitive index of reactive tissue damage^[24,25]. Similarly, TNF- α can be used as a marker to analyze the secretion of cytokines and is a sensitive marker for early trauma in tissues^[26,27]. In this study, the level of stress response of postoperative patients was more accurately measured by measuring the levels of these three indicators in postoperative patients. The results revealed that the levels of CRP, IL-6, and TNF- α in the surgical group were significantly higher than those in the microwave ablation group at 24 h after operation ($P < 0.05$). The stress response of the patients in the surgery group was even stronger, and the microwave ablation significantly reduced the patient's body trauma. This is because ultrasound-guided microwave ablation is guided by ultrasound under real-time guidance and avoids major organs such as large blood vessels in the puncture path. The microwave ablation electrode is rapidly and accurately implanted in the thyroid tumor lesions for ablation. It has the advantages of simpler operation, shorter time, less intraoperative blood loss, and less traumatic emergency response^[28,29]. Those advantages can prompt the recovery of the patient's health as soon as possible, shorten the patient's hospitalization time, and improve the patient's quality of life.

During surgical treatment of PTMC, changes in the thyroid function of the patient should cause extra attention. In this study, thyroid hormone levels were measured before, 7 d after, and 30 d after surgery in patients with microwave ablation and surgery. Thyroid function was dynamically monitored in each patient to better reflect postoperative dynamic changes of the thyroid function. Repeated-measures analysis of variance revealed that the FT3 and FT4 levels in the surgical group had a significant decrease after surgery, and the TSH increased significantly. Considering that most of the thyroid tissue was removed by surgery, the patients lost some of the endogenous thyroid function. The patients revealed a more obvious performance of hypothyroidism. In the microwave ablation group, the level of TSH slightly decreased after surgery, but the change was not obvious and there was no significant increase after surgery for a long time. This indicates that microwave ablation can better protect normal thyroid tissue than surgical resection, which is similar to the study of Baek *et al.*^[30]. It is worth noting that there was

no significant change in the FT3 and FT4 levels at the 7th and 30th days after surgery in the microwave ablation group compared with the surgical group. This indicates that microwave ablation is relatively infrequent in the thyroid. Thyroid function was still maintained at a certain level after surgery and no significant reduction in thyroid function occurred. This has important implications for patients in the clinic. If the patient's thyroid function remains stable after surgery, long-term use of thyroid hormone drugs can be avoided and the quality of life of patients can be improved.

The incidence of postoperative complications was observed in the study. The results revealed that postoperative complications occurred in 2 out of 41 patients who underwent microwave ablation. The overall incidence of complications was 4.9% in the microwave ablation group. The overall incidence of complications in the surgery group was 15.2%. There was no significant difference between the two groups ($P > 0.05$). Considering that the sample size was small in this study, the difference was not obvious and large sample data are needed. Long-term efficacy and complications should be further observed.

In summary, the use of microwave ablation for the treatment of PTMC has little risk of traumatic stress and safety. This technology can effectively shorten the length of hospital stay and improve the quality of life of patients. Due to the small damage caused by microwave ablation, the postoperative thyroid function is not significantly affected, which has a high clinical value.

ARTICLE HIGHLIGHTS

Research background

The detection rate of papillary thyroid microcarcinoma (PTMC) has increased over time. Because thyroidectomy is prone to various complications, it can cause physical and mental harm to the patient. With the rapid development of minimally invasive techniques, microwave ablation is the main method of minimally invasive thyroid treatment, and is often used for the treatment of benign thyroid nodules. However, whether this method is indicated for the treatment of patients with PTMC is still controversial.

Research motivation

In this study, microwave ablation was used to treat patients with PTMC. It is hoped that microwave ablation can achieve the same effect as thyroid surgery, and can reduce the complications caused by thyroid surgery.

Research objectives

The aim of this study was to compare the efficacy of thyroidectomy and microwave ablation in the treatment of PTMC and their trauma to the patient's body, to find a more appropriate treatment for patients.

Research methods

Eighty-seven patients diagnosed with papillary thyroid carcinoma were enrolled. There were 46 cases in the surgical group and 41 cases in the microwave ablation group. Microwave ablation and thyroidectomy were performed in each group. The operative time, intraoperative blood loss, hospitalization time, serum C-reactive protein (CPR), interleukin-6 (IL-6), and tumor necrosis factor- α (TNF- α) were observed in the two groups. The changes of thyroid-related hormones and the postoperative complications of the two groups were observed 7 d and 30 d after surgery.

Research results

The operative time, intraoperative blood loss, hospitalization time, CPR, IL-6, and TNF- α in the surgical group were significantly higher than those in the microwave ablation group. The free triiodothyronine (FT3) and free thyroxine (FT4) levels in the surgical group were significantly lower than those in the microwave ablation group, while thyroid stimulating hormone (TSH) was significantly higher than that in the microwave ablation group. The complications of the two groups were similar.

Research conclusions

Microwave ablation for the treatment of PTMC has less stress response and higher safety. It can effectively shorten the hospitalization time of patients and improve the life quality. The thyroid function of patients after operation is not affected, so microwave ablation treatment of PTMC has a high clinical value.

Research perspectives

With the development of minimally invasive treatment, minimally invasive treatment methods are increasingly applied to various diseases, so that patients can achieve therapeutic goals with minimal surgical trauma, and minimize the impact of surgical trauma on the body. Minimally invasive surgery is a new technological innovation that still requires large sample and multi-center clinical research support to evaluate long-term safety and efficacy.

REFERENCES

- 1 Ito Y, Oda H, Miyauchi A. Insights and clinical questions about the active surveillance of low-risk papillary thyroid microcarcinomas. *Endocr J* 2016; **63**: 323-328 [PMID: 26632168 DOI: 10.1507/endocrj.EJ15-0637]
- 2 Tarasova VD, Tuttle RM. Current Management of Low Risk Differentiated Thyroid Cancer and Papillary Microcarcinoma. *Clin Oncol (R Coll Radiol)* 2017; **29**: 290-297 [PMID: 28087101 DOI: 10.1016/j.clon.2016.12.009]
- 3 Dobrinja C, Pastorichio M, Troian M, Da Canal F, Bernardi S, Fabris B, de Manzini N. Partial thyroidectomy for papillary thyroid microcarcinoma: Is completion total thyroidectomy indicated? *Int J Surg* 2017; **41** Suppl 1: S34-S39 [PMID: 28506411 DOI: 10.1016/j.ijsu.2017.02.012]
- 4 Chung YS, Choe JH, Kang KH, Kim SW, Chung KW, Park KS, Han W, Noh DY, Oh SK, Youn YK. Endoscopic thyroidectomy for thyroid malignancies: comparison with conventional open thyroidectomy. *World J Surg* 2007; **31**: 2302-2306; discussion 2307-2308 [PMID: 17566819 DOI: 10.1007/s00268-007-9117-0]
- 5 Kang JB, Kim EY, Park YL, Park CH, Yun JS. A comparison of postoperative pain after conventional open thyroidectomy and single-incision, gasless, endoscopic transaxillary thyroidectomy: a single institute prospective study. *Ann Surg Treat Res* 2017; **92**: 9-14 [PMID: 28090500 DOI: 10.4174/ast.2017.92.1.9]
- 6 Liu YJ, Qian LX, Liu D, Zhao JF. Ultrasound-guided microwave ablation in the treatment of benign thyroid nodules in 435 patients. *Exp Biol Med (Maywood)* 2017; **242**: 1515-1523 [PMID: 28847173 DOI: 10.1177/1535370217727477]
- 7 Jin H, Fan J, Liao K, He Z, Li W, Cui M. A propensity score matching study between ultrasound-guided percutaneous microwave ablation and conventional thyroidectomy for benign thyroid nodules treatment. *Int J Hyperthermia* 2018; 1-7 [PMID: 30176761 DOI: 10.1080/02656736.2018.1492028]
- 8 Wu W, Gong X, Zhou Q, Chen X, Chen X, Shi B. US-guided percutaneous microwave ablation for the treatment of benign thyroid nodules. *Endocr J* 2017; **64**: 1079-1085 [PMID: 28855431 DOI: 10.1507/endocrj.EJ17-0152]
- 9 Li J, Liu Y, Liu J, Qian L. Ultrasound-guided percutaneous microwave ablation versus surgery for papillary thyroid microcarcinoma. *Int J Hyperthermia* 2018; **34**: 653-659 [PMID: 29637797 DOI: 10.1080/02656736.2018.1453092]
- 10 Sun H, Dionigi G. Influence of specialized clinic on initial treatment choice in localized thyroid cancer. *Eur J Surg Oncol* 2018 [PMID: 30322670 DOI: 10.1016/j.ejso.2018.05.040]

- 11 Teng D, Sui G, Liu C, Wang Y, Xia Y, Wang H. Long-term efficacy of ultrasound-guided low power microwave ablation for the treatment of primary papillary thyroid microcarcinoma: a 3-year follow-up study. *J Cancer Res Clin Oncol* 2018; **144**: 771-779 [PMID: 29427209 DOI: 10.1007/s00432-018-2607-7]
- 12 Mazzaferri EL. Managing thyroid microcarcinomas. *Yonsei Med J* 2012; **53**: 1-14 [PMID: 22187228 DOI: 10.3349/ymj.2012.53.1.1]
- 13 Morris LG, Sikora AG, Tosteson TD, Davies L. The increasing incidence of thyroid cancer: the influence of access to care. *Thyroid* 2013; **23**: 885-891 [PMID: 23517343 DOI: 10.1089/thy.2013.0045]
- 14 Rodrigues AC, Penna G, Rodrigues E, Castro P, Sobrinho-Simões M, Soares P. The Genetics of Papillary Microcarcinomas of the Thyroid: Diagnostic and Prognostic Implications. *Curr Genomics* 2017; **18**: 244-254 [PMID: 28659720 DOI: 10.2174/1389202918666170105094459]
- 15 Boucai L, Bernet V, Shaha A, Shindo ML, Stack BC, Tuttle RM. Surgical considerations for papillary thyroid microcarcinomas. *J Surg Oncol* 2017; **116**: 269-274 [PMID: 28513849 DOI: 10.1002/jso.24673]
- 16 Yue W, Wang S, Wang B, Xu Q, Yu S, Yonglin Z, Wang X. Ultrasound guided percutaneous microwave ablation of benign thyroid nodules: safety and imaging follow-up in 222 patients. *Eur J Radiol* 2013; **82**: e11-e16 [PMID: 22940229 DOI: 10.1016/j.ejrad.2012.07.020]
- 17 Qin M, Zou F, Zheng M, Zhao H. Systemic stress responses after laparoendoscopic single-site hepatectomy: a perspective controlled study. *Hepatogastroenterology* 2012; **59**: 1204-1207 [PMID: 22281982 DOI: 10.5754/hge11791]
- 18 Yu Y, Yanli H, Jing Z, Zhiyu H, Xia MA, Ruifang XU. Ultrasound-guided percutaneous microwave ablation for subserosal uterine fibroids. *J Minim Invasive Gynecol* 2018 [PMID: 29964178 DOI: 10.1016/j.jmig.2018.06.014]
- 19 Wang Z, Tang X, Qi X, Shi Y, Chi J, Li P, Zhai B. Feasibility, safety, and efficacy of ultrasound-guided percutaneous microwave ablation for giant hepatic hemangioma. *Int J Hyperthermia* 2018; 1-7 [PMID: 30130992 DOI: 10.1080/02656736.2018.1493541]
- 20 Hsiao CY, Huang KW. Irreversible Electroporation: A Novel Ultrasound-guided Modality for Non-thermal Tumor Ablation. *J Med Ultrasound* 2017; **25**: 195-200 [PMID: 30065492 DOI: 10.1016/j.jmu.2017.08.003]
- 21 Yan J, Qiu T, Lu J, Wu Y, Yang Y. Microwave ablation induces a lower systemic stress response in patients than open surgery for treatment of benign thyroid nodules. *Int J Hyperthermia* 2018; **34**: 606-610 [PMID: 29366346 DOI: 10.1080/02656736.2018.1427286]
- 22 Yue WW, Wang SR, Lu F, Sun LP, Guo LH, Zhang YL, Li XL, Xu HX. Radiofrequency ablation vs. microwave ablation for patients with benign thyroid nodules: a propensity score matching study. *Endocrine* 2017; **55**: 485-495 [PMID: 27905049 DOI: 10.1007/s12020-016-1173-5]
- 23 De Bernardi IC, Floridi C, Muollo A, Giaccherio R, Dionigi GL, Reginelli A, Gatta G, Cantisani V, Grassi R, Brunese L, Carrafiello G. Vascular and interventional radiology radiofrequency ablation of benign thyroid nodules and recurrent thyroid cancers: literature review. *Radiol Med* 2014; **119**: 512-520 [PMID: 24927806 DOI: 10.1007/s11547-014-0411-2]
- 24 Yao X, Huang J, Zhong H, Shen N, Faggioni R, Fung M, Yao Y. Targeting interleukin-6 in inflammatory autoimmune diseases and cancers. *Pharmacol Ther* 2014; **141**: 125-139 [PMID: 24076269 DOI: 10.1016/j.pharmthera.2013.09.004]
- 25 Vainer N, Dehlendorf C, Johansen JS. Systematic literature review of IL-6 as a biomarker or treatment target in patients with gastric, bile duct, pancreatic and colorectal cancer. *Oncotarget* 2018; **9**: 29820-29841 [PMID: 30038723 DOI: 10.18632/oncotarget.25661]
- 26 Natkaniec M, Dworak J, Hankus J, Sanak M, Pędziwiatr M, Major P, Licholai S, Budzyński A. Influence of TNF- α promoter variability on stage and grade in individuals with colorectal cancer. *Pol J Pathol* 2018; **69**: 150-156 [PMID: 30351862 DOI: 10.5114/pjp.2018.76698]

- 27 **Shen J**, Xiao Z, Zhao Q, Li M, Wu X, Zhang L, Hu W, Cho CH. Anti-cancer therapy with TNF α and IFN γ : A comprehensive review. *Cell Prolif* 2018; **51**: e12441 [PMID: 29484738 DOI: 10.1111/cpr.12441]
- 28 **Ha EJ**, Baek JH, Lee JH. The efficacy and complications of radiofrequency ablation of thyroid nodules. *Curr Opin Endocrinol Diabetes Obes* 2011; **18**: 310-314 [PMID: 21841482 DOI: 10.1097/MED.0b013e32834a9168]
- 29 **Kim JH**, Baek JH, Lim HK, Ahn HS, Baek SM, Choi YJ, Choi YJ, Chung SR, Ha EJ, Hahn SY, Jung SL, Kim DS, Kim SJ, Kim YK, Lee CY, Lee JH, Lee KH, Lee YH, Park JS, Park H, Shin JH, Suh CH, Sung JY, Sim JS, Youn I, Choi M, Na DG; Guideline Committee for the Korean Society of Thyroid Radiology (KSThR) and Korean Society of Radiology. 2017 Thyroid Radiofrequency Ablation Guideline: Korean Society of Thyroid Radiology. *Korean J Radiol* 2018; **19**: 632-655 [PMID: 29962870 DOI: 10.3348/kjr.2018.19.4.632]
- 30 **Baek JH**, Kim YS, Lee D, Huh JY, Lee JH. Benign predominantly solid thyroid nodules: prospective study of efficacy of sonographically guided radiofrequency ablation versus control condition. *AJR Am J Roentgenol* 2010; **194**: 1137-1142 [PMID: 20308523 DOI: 10.2214/AJR.09.3372]

P- Reviewer: Arisawa T, Kim ES, Knittel T **S- Editor:** Wang JL
L- Editor: Wang TQ **E- Editor:** Tan WW





Published by **Baishideng Publishing Group Inc**
7901 Stoneridge Drive, Suite 501, Pleasanton, CA 94588, USA
Telephone: +1-925-223-8242
Fax: +1-925-223-8243
E-mail: bpgoffice@wjgnet.com
Help Desk: <http://www.f6publishing.com/helpdesk>
<http://www.wjgnet.com>

